British
Society of
Echocardiography

A Minimum Dataset for a Standard Transthoracic Echocardiogram

From the British Society of Echocardiography Education Committee

Gill Wharton (Lead Author), Richard Steeds (Chair),

Jane Allen, Hollie Brewerton, Richard Jones, Prathap Kanagala, Guy Lloyd, Navroz Masani,

Thomas Mathew, David Oxborough, Bushra Rana, Julie Sandoval, Nicola Smith, Richard Wheeler.

NEW GUIDELINES

A Minimum Dataset for a Standard Transthoracic Echocardiogram

From the British Society of Echocardiography Education Committee

Gill Wharton (Lead Author), Richard Steeds (Chair),

Bushra Rana, Richard Wheeler, Nicola Smith, David Oxborough, Hollie Brewerton, Jane Allen, John Chambers, Julie Sandoval, Guy Lloyd, Prathap Kanagala, Thomas Matthew, Navroz Masani, Richard Jones.

1. Introduction

This document aims to provide a framework for performing an adult transthoracic echocardiogram (TTE) and replaces the previous Minimum Dataset published in 2005.

The layout is not only a minimum dataset but also proposes a recommended sequence in how to perform a comprehensive study.

The layout has been altered to provide a visual example of the ideal image that should be acquired in each acoustic window. This is supported by text which follows a standard layout, with the acoustic window and transducer position in the first column, followed by the modality to be used, measurements to be made at that location and an explanation if additional information is felt to be necessary.

1. 1 The BSE Education Committee recommendations are concerned with the key components expected to be performed in all standard adult transthoracic studies. This represents a Minimum Dataset that may only be sufficient when the echocardiographic study is entirely normal. If abnormalities are detected, additional views may be required to supplement those outlined in the dataset. Supplementary protocols have been completed and published to cover additional information required in certain clinical scenarios, including hypertrophic cardiomyopathy, pulmonary hypertension, assessment for mitral valve repair, mitral stenosis and assessment for percutaneous mitral commissurotomy, and Marfans syndrome. Further supplementary datasets are in preparation.

1.2 The intended benefits of these recommendations are to:

- Support cardiologists and echocardiographers to develop local protocols and quality control programs for adult transthoracic study. This Minimum Dataset provides a template against which studies in any department should be audited.
- Promote quality by defining a “minimum dataset” of descriptive terms and measurements and a systematic approach to constructing a report.
- Facilitate accurate comparison of serial echocardiograms performed in patients at the same or different sites.
- Facilitate the transition to digital echocardiography acquisition and reporting systems that utilise database (software) architecture.

1.3. There is broad agreement over what views and recordings are essential in any standard study. There is no evidence-base and this Minimum Dataset represents a consensus view on the components of a complete TTE study.

1.4. It is expected that a standard echocardiogram following these recommendations will be performed in all adults when an echocardiogram is requested and that this type of study will make up the majority of studies performed within any department, whether in the community or in hospital.

It is recognised that focused studies may be appropriate in circumstances agreed locally. Focussed TTE can either mean focussing on major abnormalities predominantly in an urgent clinical situation, eg pericardial effusion, or focussing on a particular aspect of the heart, eg longitudinal monitoring of left ventricular function. The skill level required for such studies is very high and it is expected that the patient will either have had a full standard TTE before monitoring commences or after an emergency assessment has been completed. Such studies should be clearly identified as focussed studies and are not covered by these recommendations.

1.5 When the condition or acoustic windows of the patient prevent the acquisition of one or more components of the Minimum Dataset, or when measurements result in misleading information (e.g. off-axis measurements) this should be stated.

It is recommended that any study is accompanied by a statement regarding the image quality achieved: good/fair/poor.

2. Identifying information

The images acquired should be clearly labelled with patient identifiers, including the following:

- Patient name
- A second unique identifier such as hospital number or date of birth
- Identification of the operator e.g. initials

3. ECG

An ECG should be attached ensuring good tracings to facilitate the acquisition of complete digital loops.

4. Height/weight/haemodynamic variables

Qualitative and quantitative evaluation of chamber size and function is a major component of every echocardiographic examination. Chamber dimensions may be influenced by age, sex and body size, for example the left atrium, and consideration should be given to the use of referenced ranges indexed to height or body surface area, in a similar way that velocities measured using Doppler should take account of pulse rate and blood pressure. No recommendation is made to the routine use of indexed measurements but facilities should be available to sonographers to measure height, weight, pulse rate and blood pressure at the time of an echocardiogram.

5. Duration

The exact time required for performance and reporting of a standard TTE following these recommendations is currently under review. A statement is being prepared by the BSE main council for release. The time taken for a standard TTE should include time to complete a report, and will also have to take account of the time taken for patient preparation.

6. Report

No standard TTE is complete until a report is released and is made available to the referring individual.

The majority of studies performed in a Department should be reported immediately on completion and a report available on discharge of a patient from the Echocardiography facility.

It is recognised that there are times when a review of images and further consideration is required, for example when the individual performing the scan does not hold Proficiency Accreditation and the scan requires review prior to release, although this should be done as soon as possible.

7. Chaperones

A standard TTE is not considered an intimate examination but performance still requires sensitivity. Chaperones should not usually be required for standard TTE but for all TTE studies, patients should be offered a gown.

Echocardiography departments should send out an information leaflet with any appointment. This should include a statement that a relative or friend could accompany the patient to act as a chaperone during the study if preferred. If a friend or relative cannot attend, the leaflet should include an offer to provide a chaperone if requested by the patient. This leaflet should either offer a chaperone by mutual arrangement or, if facilities and personnel allow, a chaperone to be provided on request when the patient arrives.

A notice should be displayed in the Echocardiography department where it can be seen by patients repeating the offer of a chaperone if requested.

In practice, it is expected that the majority of patients would not need or have a chaperone.

List of abbreviations.

1. Views:

PLAX parasternal long axis

PSAX parasternal short axis

A4C apical four chamber

A2C apical two chamber

A5C apical five chamber

SC subcostal

SSN suprasternal

ALAX apical long axis or apical three chamber

2. Modality:

PW pulse wave Doppler

CW continuous wave Doppler

CFM colour Doppler

TDI tissue Doppler imaging

3. Measurement and explanatory text:

LV left ventricle
LA left atrium
MV mitral valve
AV aortic valve
Ao aorta
LVOT left ventricular outflow tract
RV right ventricle
RA right atrium
PV pulmonary valve
RVOT right ventricular outflow tract
L/R PA left/right pulmonary artery
RL/RU/LL/LUPV right lower/right upper/left lower/left upper pulmonary vein
TV tricuspid valve
IVC inferior vena cava
STJ sinotubular junction
LVIDd/s left ventricular internal dimension in diastole and systole
IVSd/s interventricular septal width in diastole and systole
LVPWd left ventricular posterior wall width in diastole
PHT pressure half-time
RVd right ventricular cavity diameter in diastole
VTI velocity time integral
RWMA regional wall motion abnormality
TAPSE tricuspid annular plane systolic excursion
MAPSE mitral annular plane systolic excursion

VIEW	Modality	Measurements	Explanatory Note	Image
PLAX	2D	LVIDd/s, IVSd, LVPWd (either 2D or M mode measurement)	LV cavity size, wall thickness, radial function	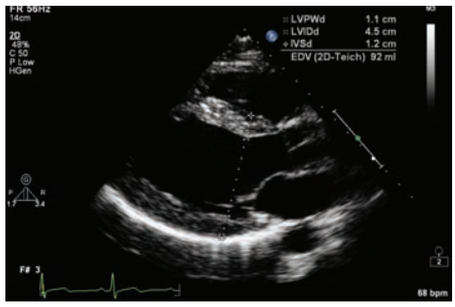
		LA size (end ventricular systole)	LA appearance MV leaflet & annulus appearance & function: - thickness, mobility, calcification, commissural fusion, sub-valve apparatus	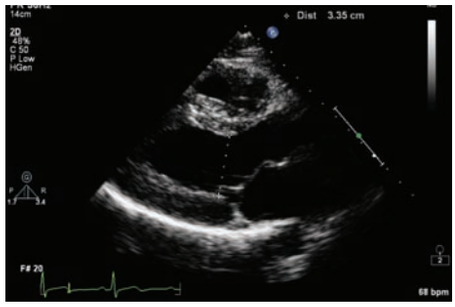
		Proximal RVOTd	AV/LVOT appearance & function	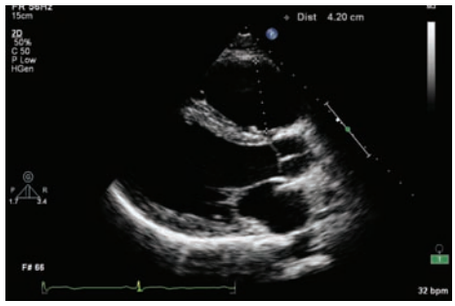
		Annulus, sinuses, ST junction, proximal ascending aorta (inner edge to inner edge, at widest diameter)	Aortic root – appearance & function	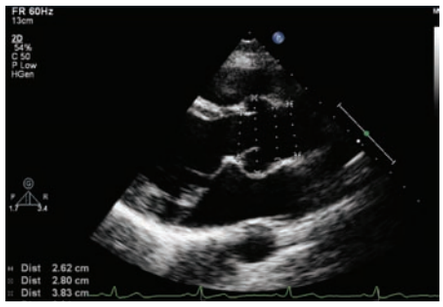
PLAX	2D	LVOT for AV area in mid systole.	Approximately same location as the PW sample volume in the A5C view (measured in the LVOT up to 1cm from the annulus)	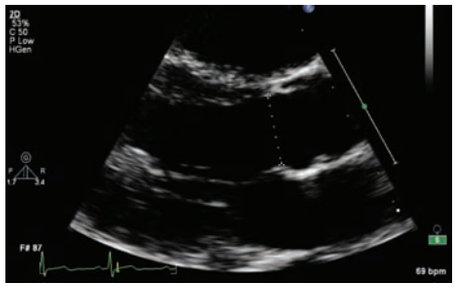
		Proximal ascending aorta at widest diameter (inner edge to inner edge)	Tilted superiorly to demonstrate mid ascending aorta	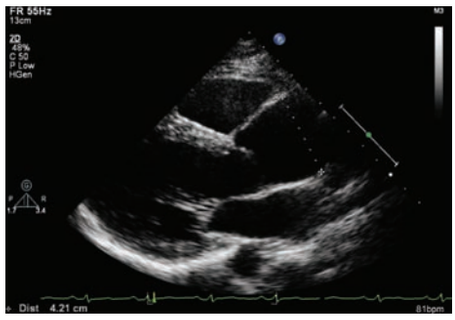

PLAX	M mode	Aortic root (end diastole) Maximum LA size (end systole), providing 2D image is on axis	Aortic valve at leaflet tips	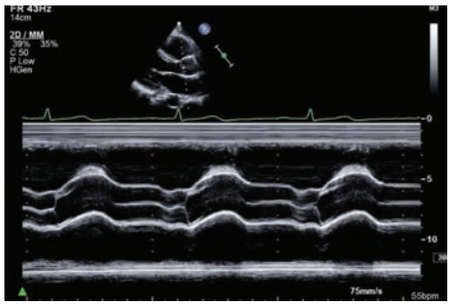
		MV E-septal separation	Mitral valve at leaflet tips	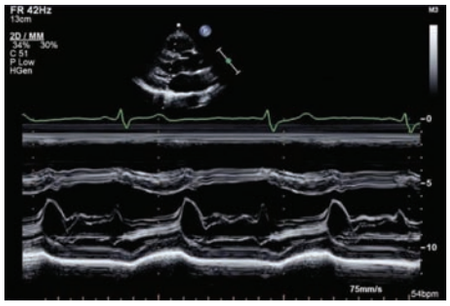
PLAX	M mode	LVIDd/s, IVSd, LVPWd (either/or 2D measurement)	Left ventricle, just distal to MV leaflet tips	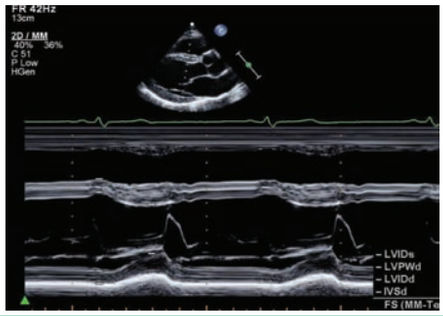
PLAX	CFM	AR/MR vena contracta	Look for AR/MR with colour box over jet Adjust Nyquist limit: 50-60 cm/s	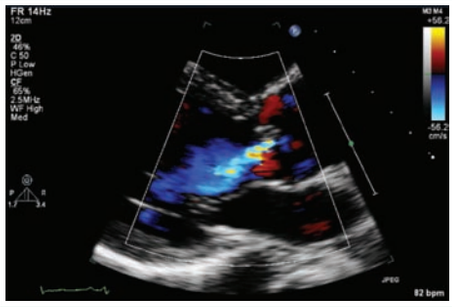
PLAX RV inflow	2D		RV cavity size & function RA, IVC, +/- coronary sinus TV – appearance & function	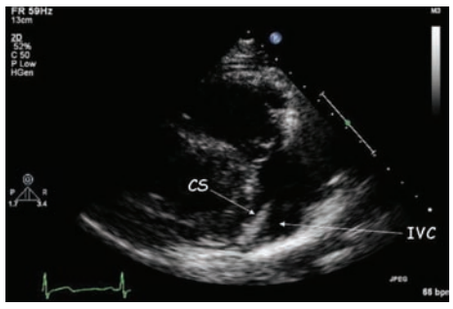
	CFM		TV inflow, TR	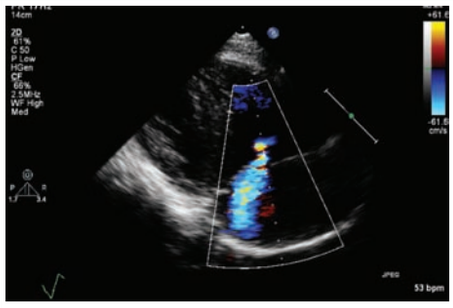

PLAX RV inflow	CW	TR V_{max}	If good alignment with jet	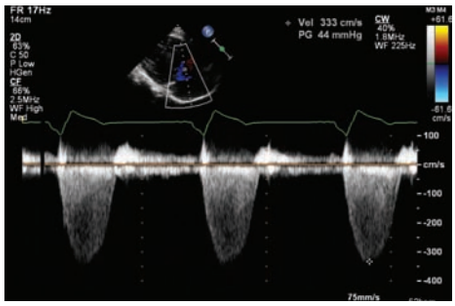
PLAX RV out-flow	2D	Distal RVOT	RVOT, PV, main PA, LPA	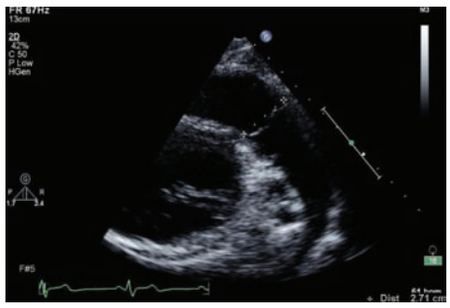
	CFM		RVOT, PA, PS, PR Optional to PSAX	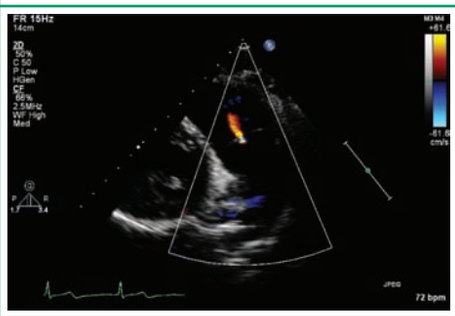
	PW		Optional to PSAX	
	CW	V_{max}, V_{mean} V_{max} end diastole	Optional PS Proximal LPA stenosis PR	
PSAX	2D 2D	Proximal RVOT diameter PV annulus, main PA	RVOT (function) AV (appearance & function) LA /atrial septum TV (appearance & function) PV, main PA	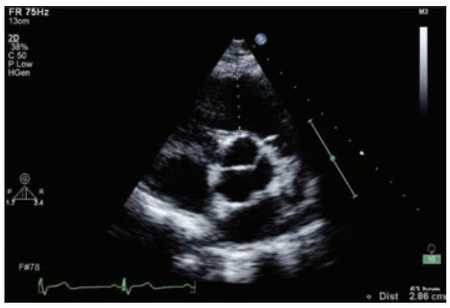 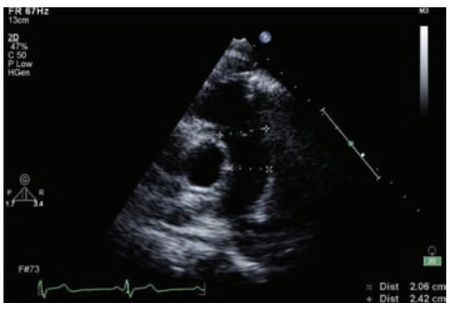

PSAX inflow			Proximal branch PA's	
PSAX outflow	CFM		Ao/LA Atrial septum IVC TV inflow, TR	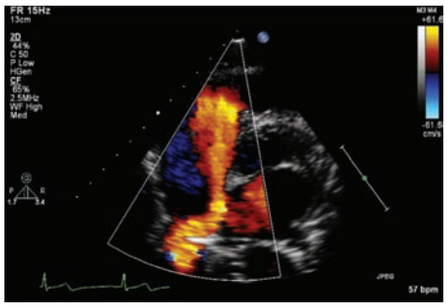
			PA (PS, PDA)	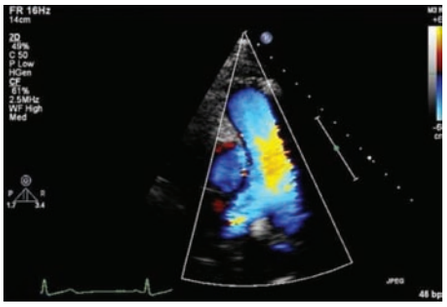
	CFM		RVOT (PR)	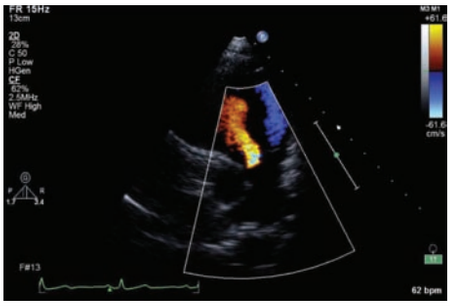
	PW	V_{max}, V_{mean}, VTI	RVOT (just proximal to PV)	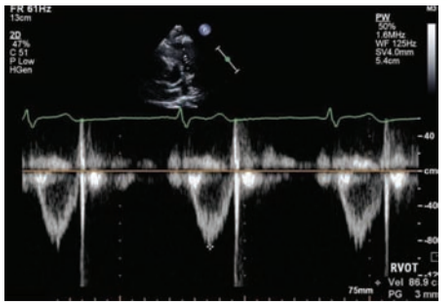
	CW	PS (V_{max}, V_{mean}) PHT	PS PR density & contour of signal	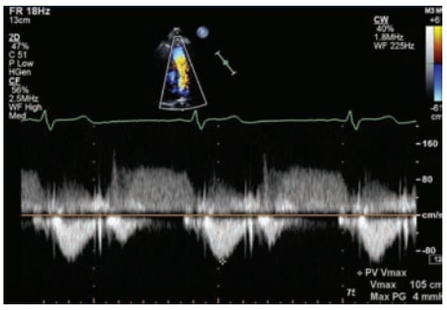

		PR V_{max} End diastolic PA pressure	End diastole	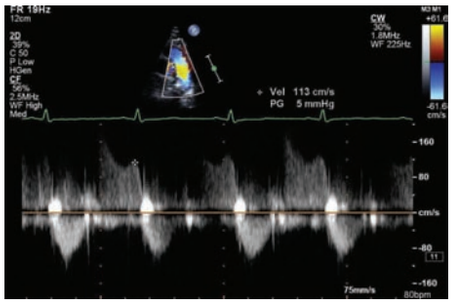
PSAX outflow	CW	PR V_{max} Mean diastolic PA pressure	Early diastole	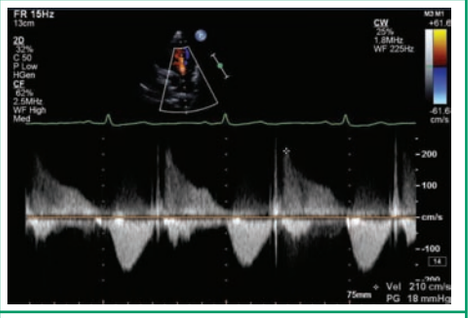
PSAX base	2D		MV leaflet & annulus: - appearance & function - thickness, mobility, calcification, commissural fusion, sub-valvar apparatus	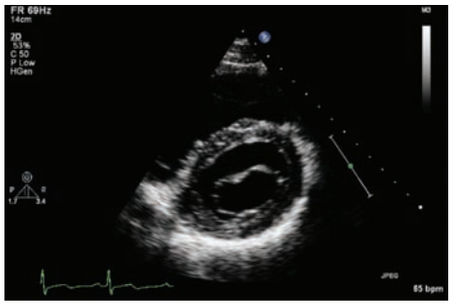
PSAX mid	2D		Sweep beam from base to apex Radial systolic function/regional wall motion abnormalities Integrity of ventricular septum	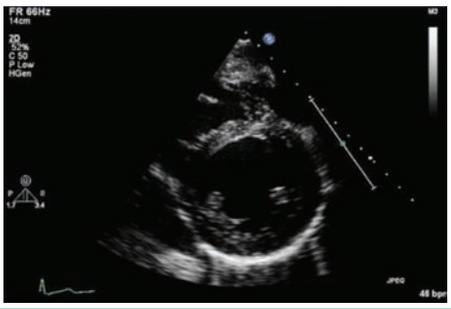
PSAX	CFM CFM		Sweep beam from base to apex Integrity of ventricular septum VSD's (congenital/post infarct)	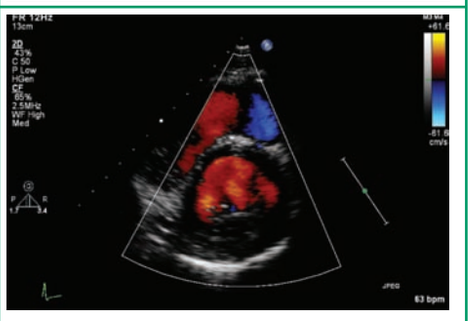 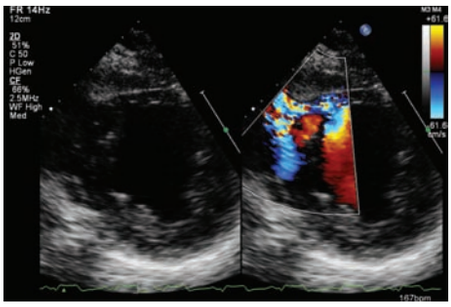

A4C	2D		LV cavity size, wall thickness (IVS, lateral) Longitudinal & radial function: RWMA's (inferoseptal & anterolateral) MV/TV appearance & function Atrial septal mobility	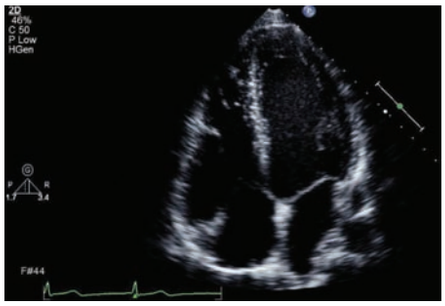
		Area/volume	LV end diastolic area/volume (BSA indexed)	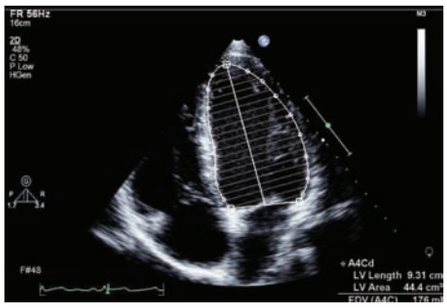
			LV end systolic area/volume (BSA indexed)	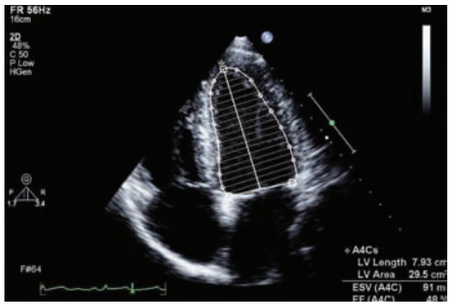
A4C	2D	LA area/volume	LA size (measured at end ventricular systole and BSA indexed)	
	M mode	TAPSE/MAPSE	TV/MV annulus Optional to tdi	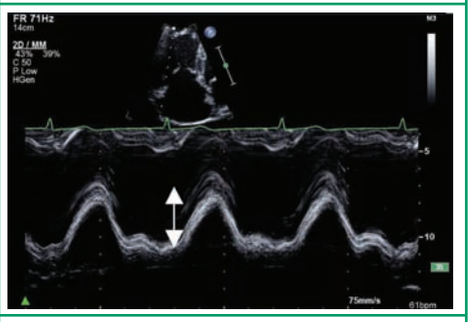
	CFM	Quantitative assessment of MR. Use PLAX to measure vena contracta	MV inflow, MR Refer to MR dataset	

			RLPV either/or RUPV LUPV, LLPV can also be imaged	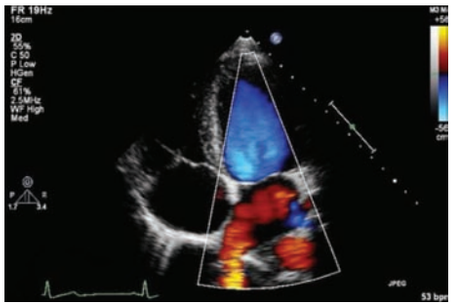
A4C	PW	E V_{max}, A V_{max}	LV inflow (MV tips)	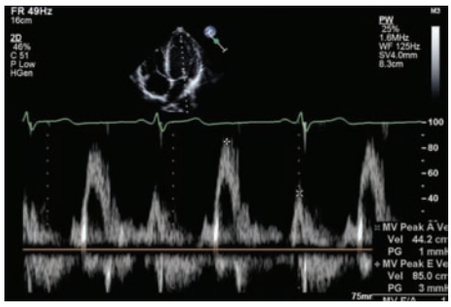
		Deceleration time		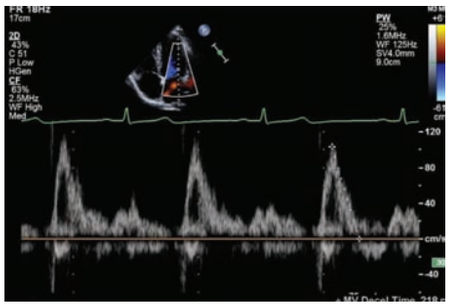
		PV_S/PV_D PVa a_{dur}-A_{dur}	Optional Right lower pulmonary vein	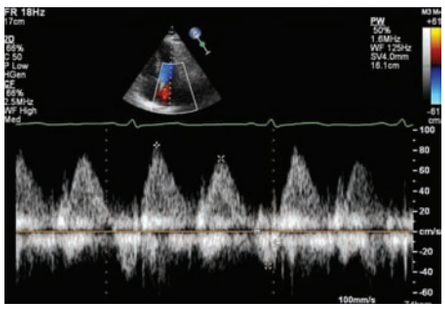
	CW	LV dP/dT (mmHg/s)	MR (shape & density of signal)	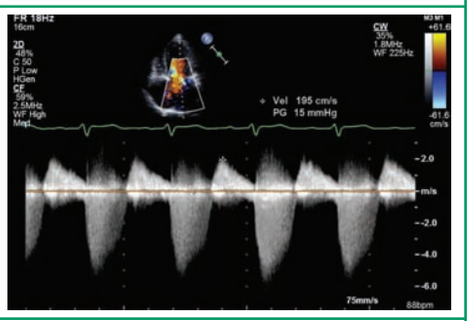
A4C	TDI	e', a', s'	Septal & lateral LV annulus Optional lateral RV	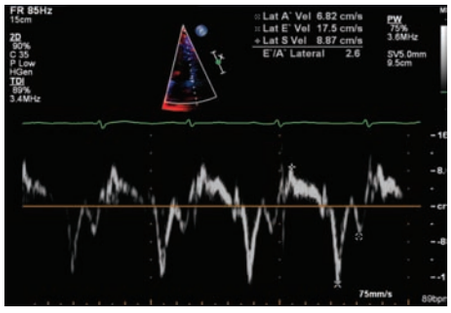

A5C	2D		LV cavity size, wall thickness, function LVOT AV appearance & function	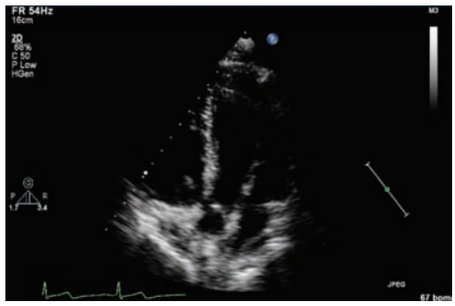
	CFM	Quantitative assessment of AR	LVOT, AR	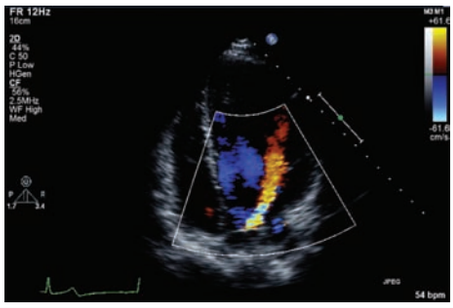
	PW	V_{max} VTI (stroke volume, cardiac output)	LVOT	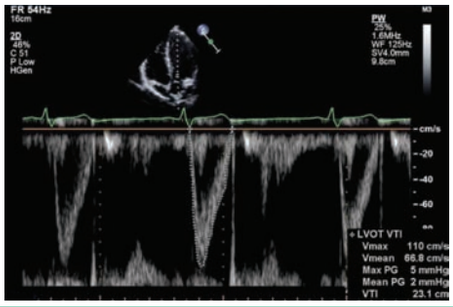
A5C	CW	V_{max}, VTI		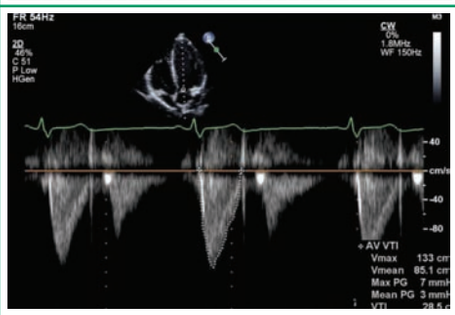
			AR	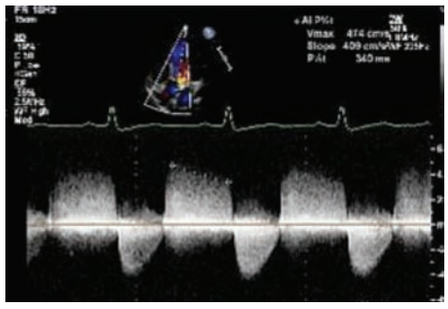
		Isovolumic relaxation time (IVRT)	Sample flow midway between LVOT & MV	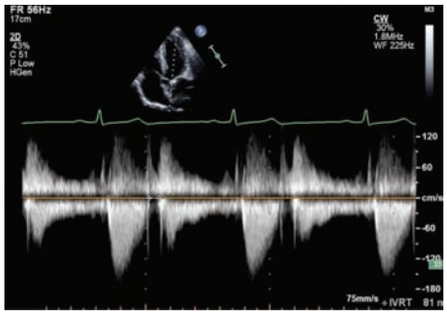

A2C	2D		LV cavity size, wall thickness: -function (anterior, inferior)	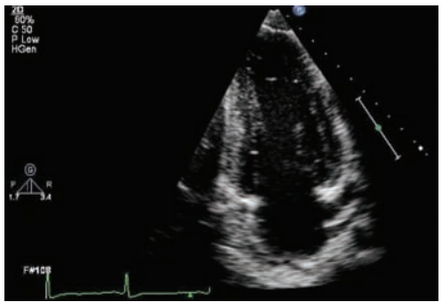
A2C	2D	Area/volume	LV end diastolic area/volume	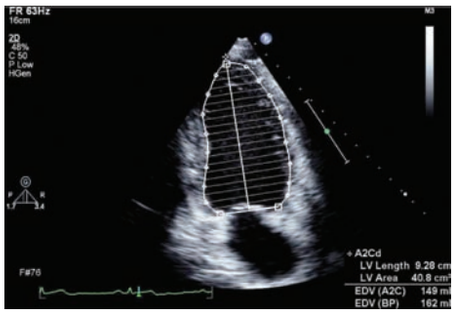
			LV end systolic area/volume	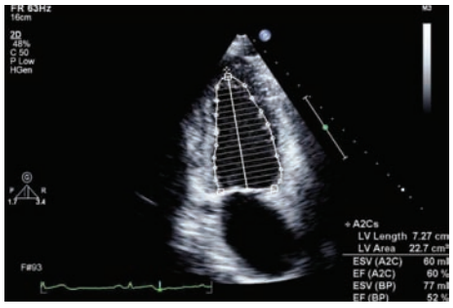
		LA area/volume (measure at end ventricular systole) Modified Simpsons or area length method	LA size	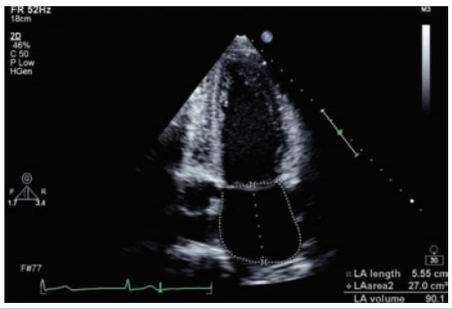
	CFM		LV inflow, MR	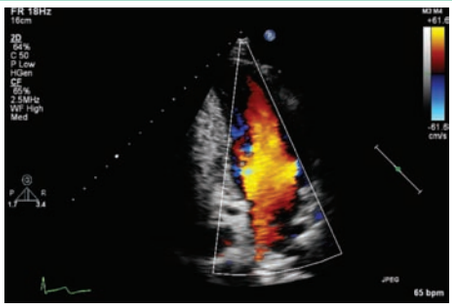
	PW optional	E, A, DT, IVRT	LV inflow (MV tips)	
	CW optional	V_{max}, V_{mean}, PHT	MS MR	

ALAX	2D		LV cavity size, wall thickness: -function (anteroseptal & inferolateral) AV/LVOT appearance & function	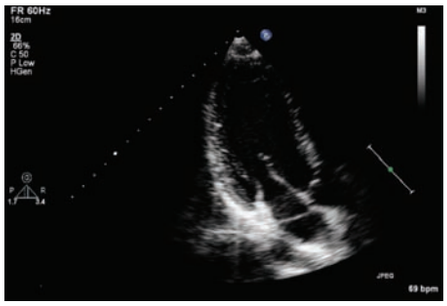
	CFM		LVOT, AR LV inflow, MR	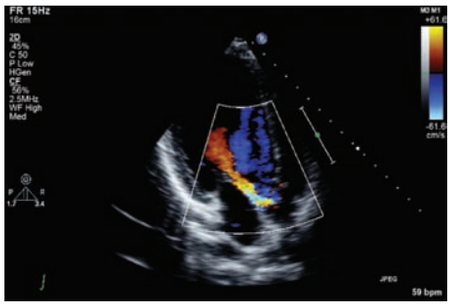
	PW optional	E, A, DT, IVRT VTI	LV inflow (MV tips) LVOT	
	CW optional	V_{max}, V_{mean}, PHT V_{max}, V_{mean} AR PHT	MS MR LVOT, AS LVOT, AR	
Modified A4C	2D	TV annulus Optional: Mid RV diameter RV length (base to apex) RA area	RV cavity size & function RA size	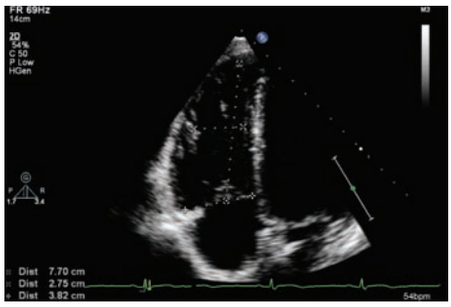
	CFM		TV inflow, TR	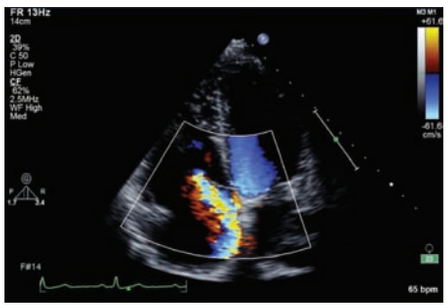
Modified A4C	PW	E V_{max}	Optional RV inflow (TV leaflet tips)	

	CW	V_{max} (PAP, RV systolic pressure)	TR	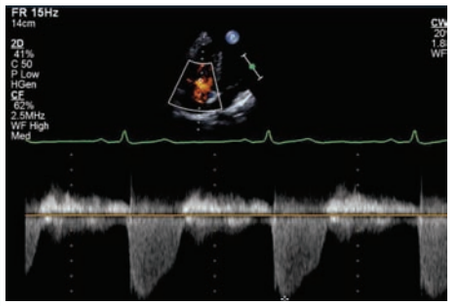
SC4C	2D		4 chamber structures, atrial septum	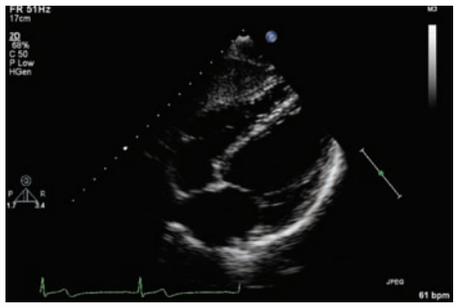
	CFM		Atrial septum Consider reducing Nyquist limit to detect low velocity flow	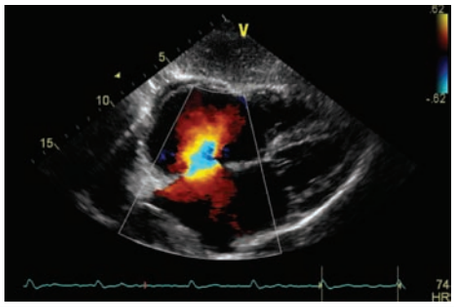
SCSAX	2D		IVC, hepatic vein (modified view)	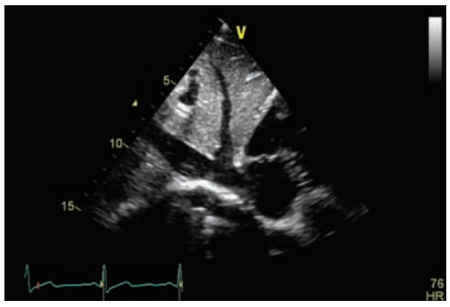
	M mode	Size & respiratory variation ("sniff")	IVC just proximal to hepatic vein	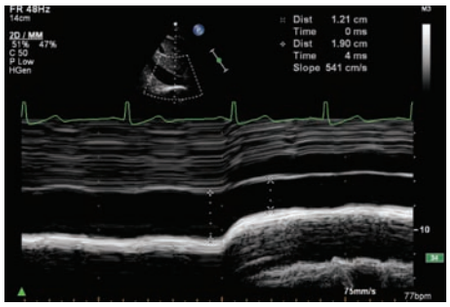
	2D		Optional: SAX structures Atrial septum, TV, RVOT, PV, PA's	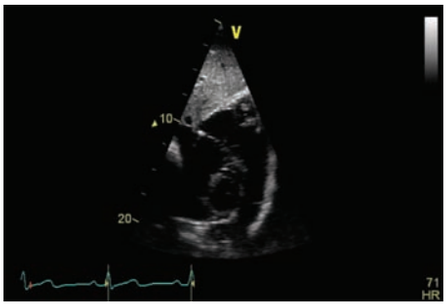

	2D		Optional Abdominal aorta (modified view)	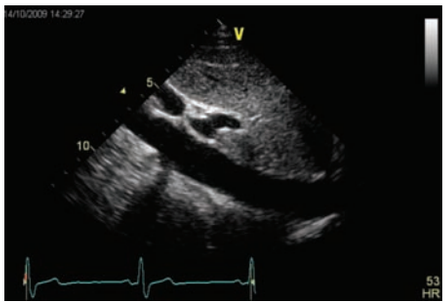
SCSAX	PW		Optional Hepatic veins	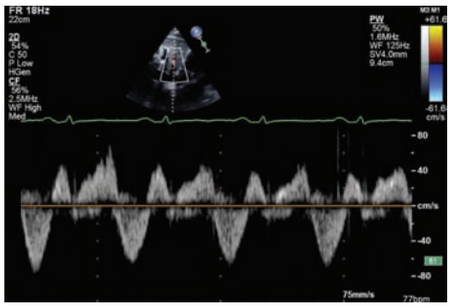
			Optional Abdominal aorta	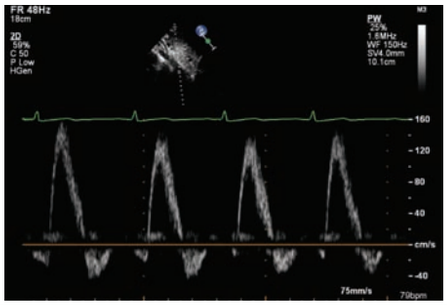
SSN	2D		Arch	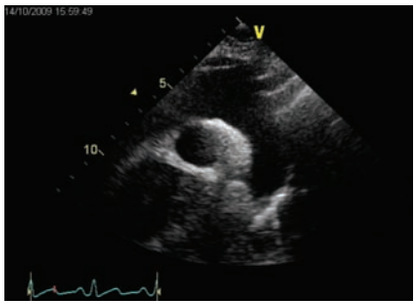
	CFM		Arch, coarctation, PDA, RPA	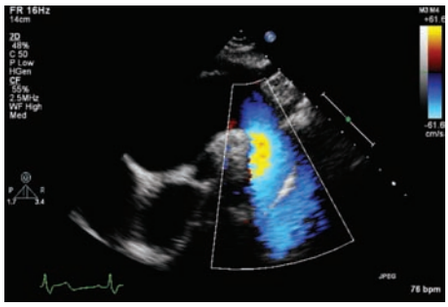
SSN	CW	V_{max}	Descending aorta with imaging probe, if good alignment with jet Descending aorta with non imaging probe, if poor jet alignment with imaging probe